

WORLD JOURNAL OF GASTROENTEROLOGY, HEPATOLOGY AND ENDOSCOPY



Wriggling Worms in The Gut During Endoscopy

Park J and
Hye Oh E*

Department of Gastroenterology, Haeundae Paik Hospital, Inje University College of Medicine, Busan, Korea

Article Information

Article Type: Clinical Image

Journal Type: Open Access

Volume: 31 Issue: 7

Manuscript ID: wjghe-31-114794

Received Date: 09 Apr 2026

Accepted Date: 22 Apr 2026

Published Date: 26 Aug 2026

*Corresponding Author:

Eun Hye Oh,

Department of Gastroenterology, Haeundae Paik Hospital, Inje University College of Medicine, 875, Haeundae-ro, Jwa 4-dong, Haeundae-gu, Busan, 48108, Korea

Citation:

Hye Oh E (2026). Wriggling Worms in The Gut During Endoscopy. World J Gastroenterol Hepatol Endosc. 31(7); 1-2

AUTHOR CONTRIBUTION:

Resources, writing and approval of final manuscript by J Park and EH Oh. The Institutional Review Board approved the study protocol (approval no. HPIRB 2021-05-029).

Copyright: © 2026, Hye Oh E, *et al.*, This is an open-access article distributed under the terms of the Creative Commons Attribution 4.0 international License, which permits unrestricted use, distribution and reproduction in any medium, provided the original author and source are credited.

QUESTION: IMAGE 1

A 71-year-old man presented to the outpatient clinic with a 10-hour history of severe cramping epigastric pain. He reported that he ate sea eel sashimi a day ago. Six months prior, he underwent endoscopic retrograde cholangiopancreatography (ERCP) and cholecystectomy for stones in the common bile duct and gallbladder. He had no other significant medical history. He reported approximately 2 oz of alcohol consumption every other day and no tobacco or illicit drug use. His vital signs were within normal limits. On physical examination, tenderness of the epigastrium was noted, with soft and flat abdomen. The initial laboratory test results were unremarkable, including liver enzymes. Esophagogastroduodenoscopy showed a light-gray colored, 2.5 cm-length linear worm wriggling on the posterior wall of the lower body of the stomach. One side of the worm penetrated into the gastric wall, with the mucosa showing localized erythema, swelling, and exudate. The worm and surrounding gastric mucosa were grasped with forceps and removed slowly and gently (Figure 1). What is your diagnosis and appropriate management?

KEYWORDS: Parasite; Anisakis; *Trichuris trichiura*; Whipworm.

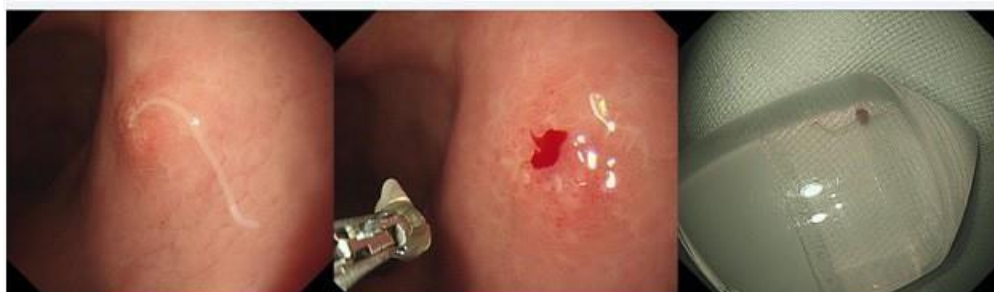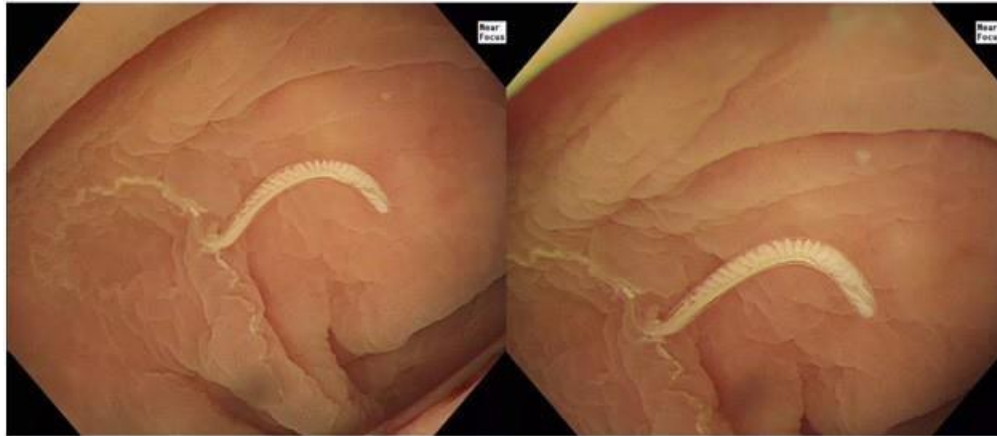


Figure 1

QUESTION: IMAGE 2

A 62-year-old woman underwent screening colonoscopy. She had been asymptomatic and had been taking statins for dyslipidemia for the past 3 years. Alcohol, tobacco, or illicit drug use was excluded. Her vital signs, physical examination, and laboratory test results were unremarkable. Colonoscopy showed a light-yellow

colored, 3 cm-length linear worm wriggling on the cecum. On closer examination, a thin tail of at least 6 cm in length was buried beneath the mucosa. The part outside the mucosa contained spiral and tubular structures covered with transparent integuments (Figure 2). What is your diagnosis and appropriate management?

**Figure 2****ANSWER TO IMAGE 1: ANISAKIS**

Anisakiosis is a food-borne parasitic infestation mediated by raw or undercooked marine fish from the Atlantic, Mediterranean, Pacific, and Antarctic seas. Eggs spawned by larvae in the gastrointestinal tract of the host are shed into the water, and fish eat hatched larvae. The fish with larvae living inside the gastrointestinal tract or muscle are eaten by bigger fish or sea mammals, and the life cycle of *Anisakis* ends. When ingested by humans, larvae invade the gastric mucosa and cause necrosis. Epigastric pain, nausea, vomiting, and hematemesis, can occur. Larvae can be removed endoscopically, but gentle manipulation should be warranted to prevent the cutting of the larvae with their head inside the gastric wall. No further anti-helminthic medicine (albendazole) is needed unless extraction of the whole body is impossible. However, as time goes on after symptom onset, larvae can completely hide beneath the mucosa, thereby making the direct observation and removal difficult. Therefore, in patients with a reasonable diet history, endoscopy should be performed immediately to prevent delayed diagnosis and unnecessary surgery [1]. With improvements in the hygiene and advent of medicine, most soil-mediated parasitic diseases have markedly decreased. However, zoonoses, especially food-borne diseases, is steadily increasing. With globalization, food from other countries is available in the market, thereby people worldwide can be affected by anisakiosis. Recently, it has been revealed that *Anisakis* can cause allergic reactions to humans. Some of the allergens are thermostable, thereby causing allergies even after eating cooked fish [2].

ANSWER TO: IMAGE 2: TRICHURIS TRICHIURA

Trichuris trichiura, the so-called whipworm is mediated by embry-

onated eggs-contaminated soil or food. It is prevalent in tropical and sub-tropical regions. After being eaten by the hosts, the eggs hatch in the proximal colon, and larvae make a tunnel by penetrating epithelial cells at the crypt base. After growing up, their posterior ends stick out into the lumen and release eggs. While a few worms cause mild or no symptoms, dysentery, abdominal pain, diarrhea, hematochezia, and rectal prolapse can occur with heavy infestation (≥ 800 worms). In children, it can cause malnutrition and growth retardation. Diagnosis is based on the presence of eggs in the stool. Anti-helminthic medicine (albendazole or mebendazole) and hygiene improvement are necessary for treatment and prevention. With anti-helminthic programs by the WHO since 2001, the prevalence declined markedly in Asia, but not in Latin America and sub-Saharan Africa. Therefore, the worldwide prevalence declined by only 2% during 2005-2015. With increasing interest in organic vegetables worldwide, eggs which survive below freezing temperatures are occasionally observed in food and whipworm infestation is no longer an endemic disease [3].

REFERENCES

1. Won Hyun L, Seung Seok Y, Hyun Jin K, et al. Endoscopic and Clinical Characteristics of Gastrointestinal Parasite Infections. *Korean J Gastrointest Endosc.* 2007; 35: 304-312.
2. Morozińska-Gogol J. *Anisakis* spp. as etiological agent of zoonotic disease and allergy in European region – an overview. *Ann Parasitol.* 2019; 65(4):303-314.
3. Else KJ, Keiser J, Holland CV, et al. Whipworm and roundworm infections. *Nat Rev Dis Primers.* 2020; 6(1):44.